

Ward's White Rat Model

Rattus rattus

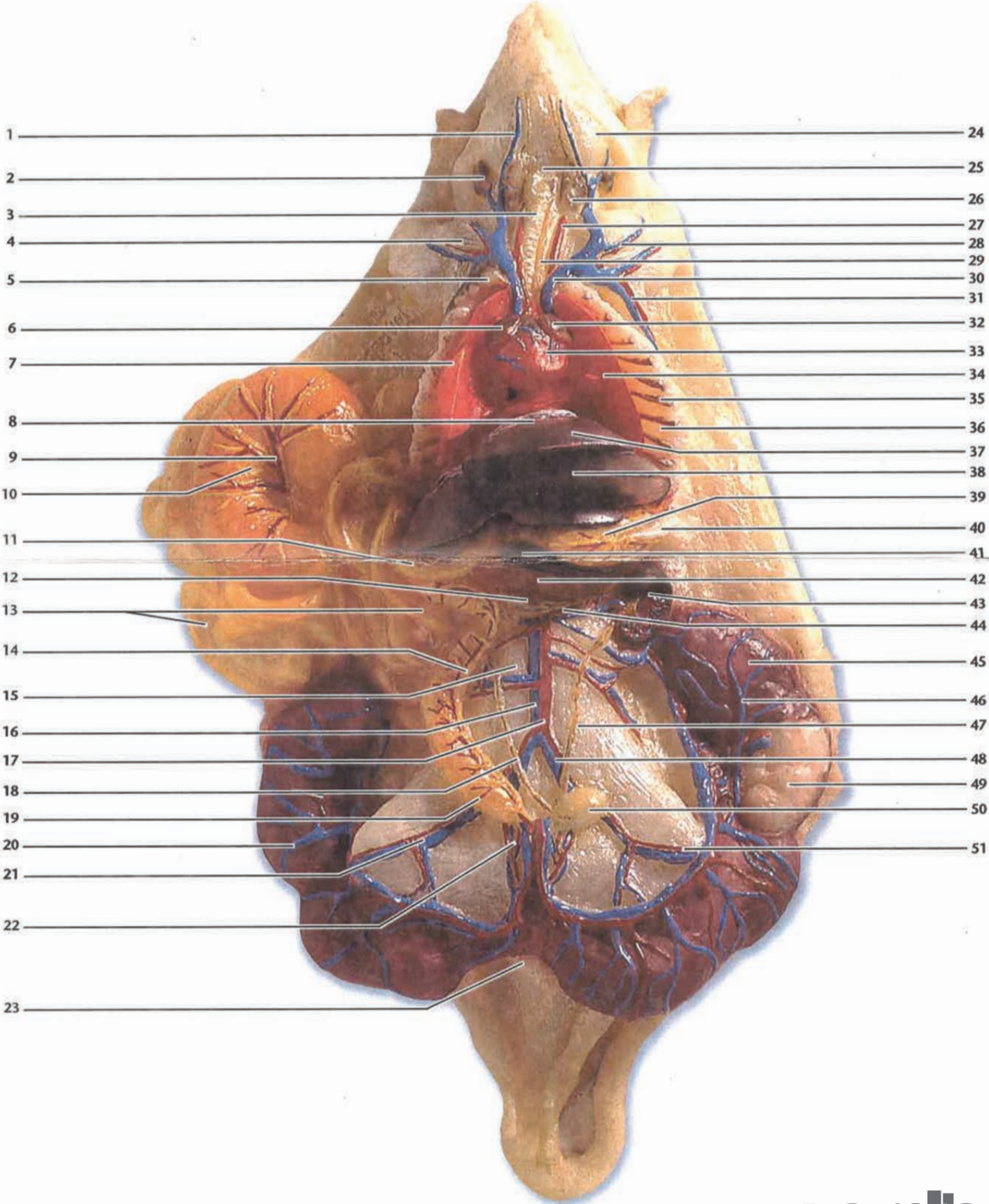
470014-422

Key to Anatomical Structures

Ventral View

1. External Jugular Vein
2. Parotid Gland
3. Trachea
4. Radial Nerve
5. Thymus
6. Right Atrium
7. Right Lung
8. Diaphragm
9. Superior Mesenteric A/V
10. Caecum
11. Duodenum
12. Pancreas
13. Small Intestines
14. Inferior Mesenteric A/V
15. Ileo Lumbar A/V
16. Vena Cava
17. Abdominal Aorta
18. Ureter
19. Colon
20. Uterus with Fetal Rats
21. External Iliac A/V
22. Internal Iliac A/V
23. Anus
24. Masseter Muscle
25. Hyoid
26. Mandibular Gland
27. Carotid Artery
28. Brachial Artery and Vein
29. Esophagus
30. Left Precava
31. Lateral Thoracic Artery
32. Left Atrium
33. Ventricle
34. Left Lung
35. Intercostal A/V
36. Rib
37. Median Lobe of Liver
38. Left Lateral Lobe of Liver
39. Stomach
40. Omentum
41. Caudate Lobe of Liver
42. Spleen
43. Kidney
44. Renal A/V
45. Uterus
46. Uterine Vein
47. Ureter
48. Common Iliac A/V
49. Fetus
50. Urinary Bladder
51. Femoral Artery

White Rat Model (Ventral View)



- 1 _____
- 2 _____
- 3 _____
- 4 _____
- 5 _____
- 6 _____
- 7 _____
- 8 _____
- 9 _____
- 10 _____
- 11 _____
- 12 _____
- 13 _____
- 14 _____
- 15 _____
- 16 _____
- 17 _____
- 18 _____
- 19 _____
- 20 _____
- 21 _____
- 22 _____
- 23 _____
- 24 _____
- 25 _____
- 26 _____
- 27 _____
- 28 _____
- 29 _____
- 30 _____
- 31 _____
- 32 _____
- 33 _____
- 34 _____
- 35 _____
- 36 _____
- 37 _____
- 38 _____
- 39 _____
- 40 _____
- 41 _____
- 42 _____
- 43 _____
- 44 _____
- 45 _____
- 46 _____
- 47 _____
- 48 _____
- 49 _____
- 50 _____
- 51 _____