

Ward's Human Brain Model

470029-586

Key to Anatomical Features

Inferior Aspect

1. Transition zone between Olfactory bulb and tract
2. Gyrus rectus
3. Infundibulum (pituitary stalk)
4. Optic nerve (II)
5. Anterior perforated substance
6. Mammillary bodies
7. Crus cerebri
8. Oculomotor nerve (III)
9. Trochlear nerve (IV)
10. Trigeminal nerve (V)
11. Vestibulocochlear nerve (VIII)
12. Flocculus of cerebellum
13. Abducens nerve (VI)
14. Glossopharyngeal nerve (IX)
15. Vagus nerve (X)
16. Cerebellar hemisphere
17. Hypoglossal nerve (XII)
18. Gray matter of the spinal cord
19. Longitudinal fissure (sagittal fissure)
20. Olfactory sulcus (termination)
21. Olfactory bulb
22. Gyrus rectus
23. Orbital gyri
24. Olfactory tract
25. Frontal lobe
26. Optic chiasm
27. Ophthalmic nerve
28. Temporal lobe
29. Optic tract
30. Maxillary nerve
31. Tuber cinereum
32. Mandibular nerve (trigeminal ganglion)
33. Semilunar ganglion
34. Trigeminal nerve (V) - motor root
35. Trigeminal nerve (V) - sensory root
36. Vestibulocochlear nerve (VIII)
37. Facial nerve (VII) and nervus intermedius
38. Pons
39. Pyramids
40. Olive
41. Tonsil of cerebellum
42. Accessory nerve (XI)

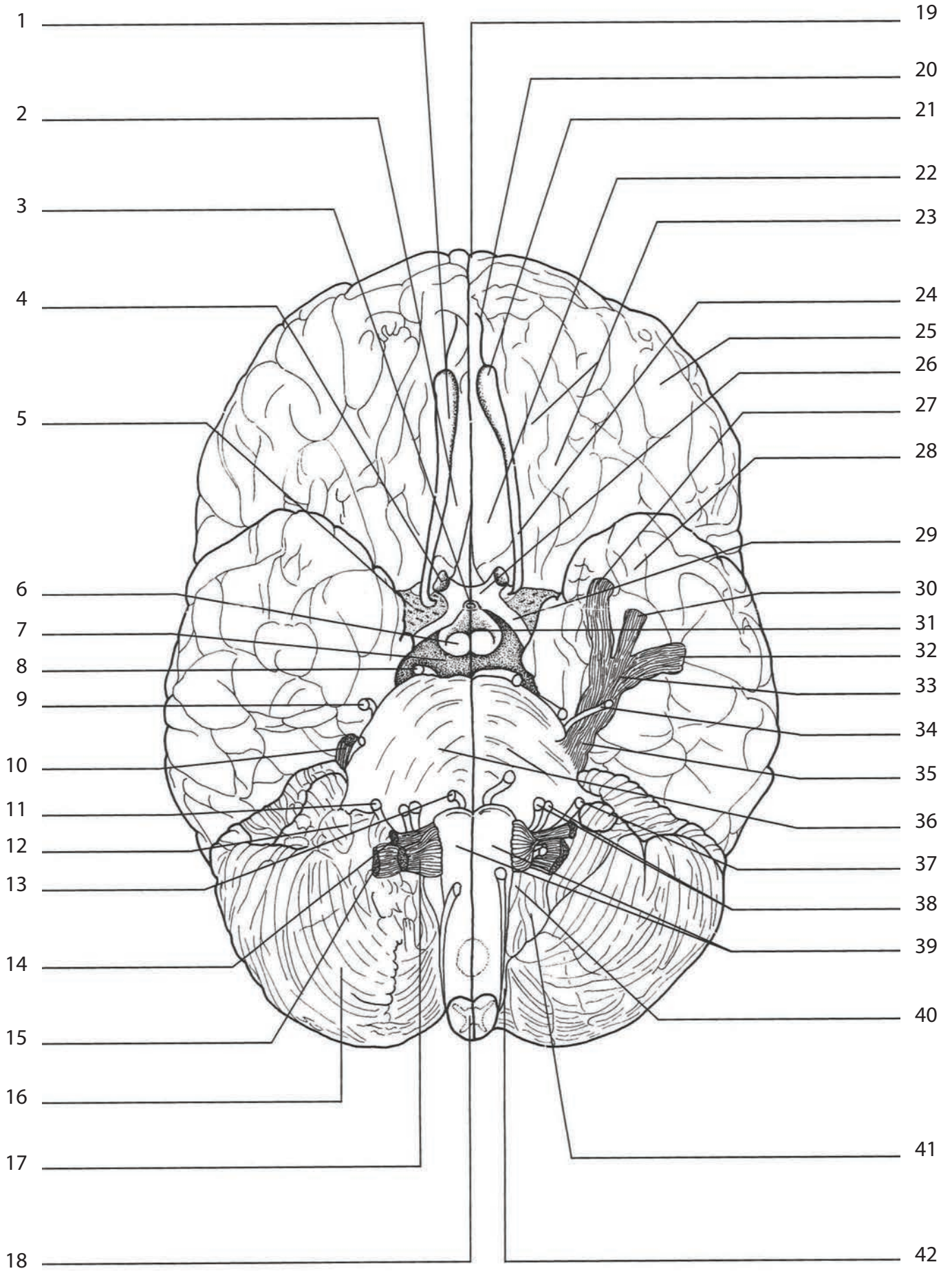
Medial Aspect (Sectioned)

43. Postcentral sulcus
44. Pineal body
45. Tectum
46. Parieto-occipital sulcus
47. Calcarine sulcus
48. Arbor vitae
49. Superior medullary velum
50. Cerebellum (sectioned)
51. Cerebellum
52. Cerebral aqueduct (of Sylvius)
53. Hypothalamic sulcus
54. Region of pyramidal decussation
55. Central sulcus (of Rolando)
56. Thalamus (3rd ventricle)
57. Stria medullaris of thalamus
58. Fornix
59. Interventricular foramen (of Monro)
60. Lateral Ventricle (cavity)
61. Septum pellucidum (shown on right hemisphere only)
62. Corpus collosum
63. Cingulate gyrus
64. Interthalamic adhesion
65. Olfactory bulb
66. Lamina terminalis
67. Optic chiasm (cut)
68. Pituitary stalk
69. Tuber cinereum
70. Mammillary body (cut)
71. Trigeminal ganglion (n. V)
72. Pons
73. Medulla oblongata

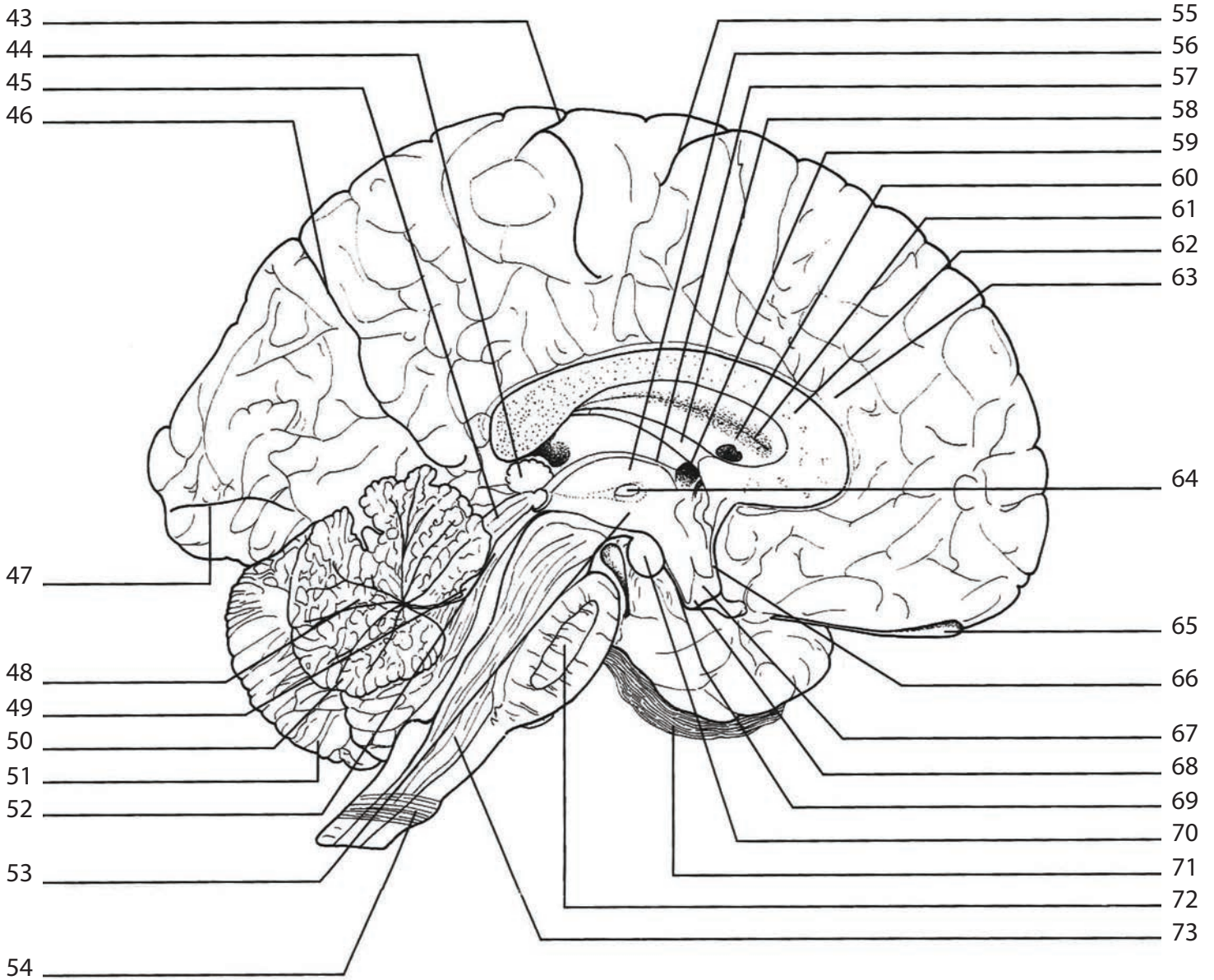
Lateral Aspect

74. Precentral gyrus
75. Frontal lobe of left cerebral hemisphere
76. Lateral sulcus
77. Temporal lobe
78. Pons
79. Central sulcus
80. Postcentral gyrus
81. Parietal lobe
82. Parietooccipital sulcus
83. Occipital lobe
84. Cerebellum

Inferior Aspect



Medial Aspect (Sectioned)



Lateral Aspect

