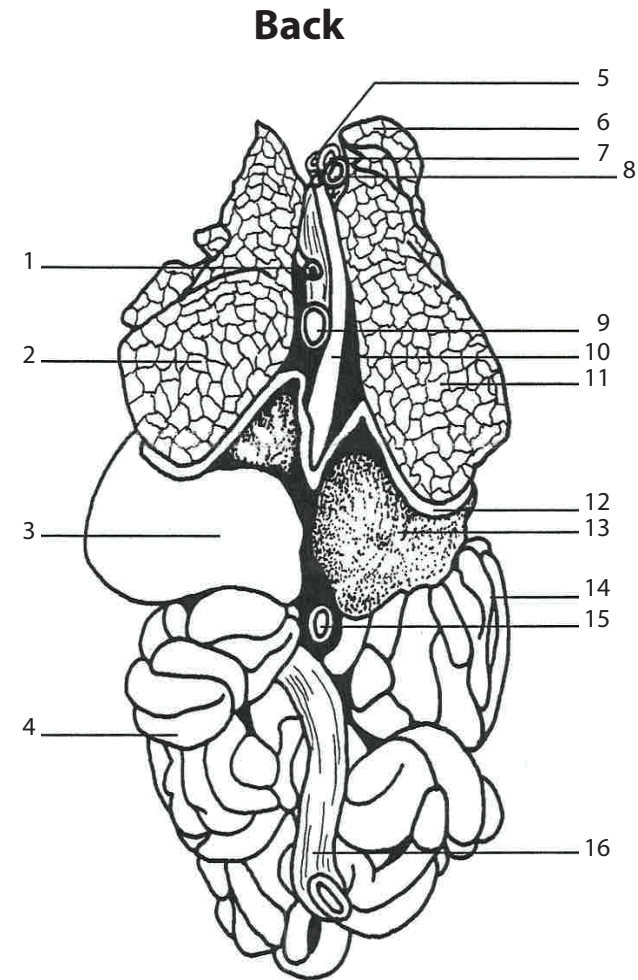
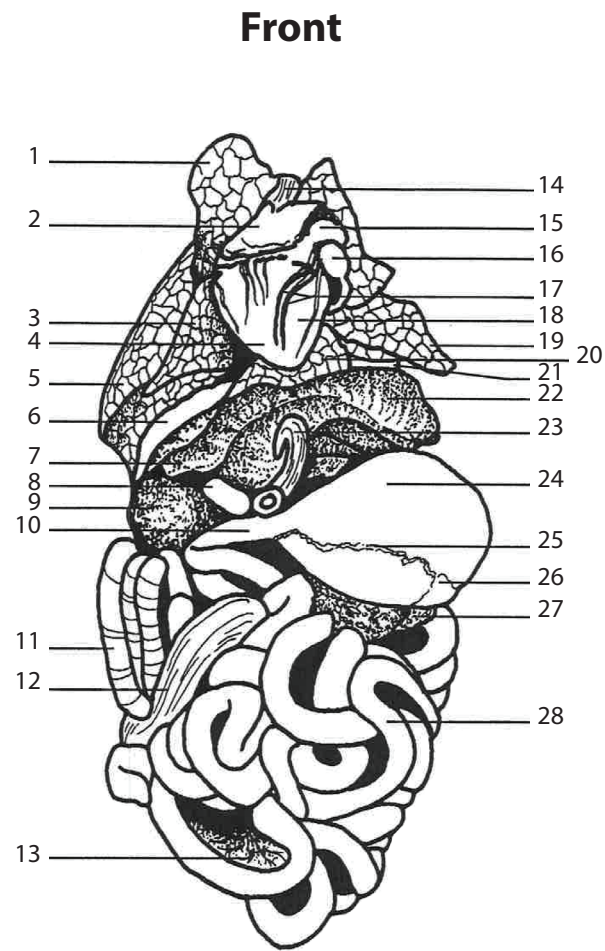


Internal Organs



- | | |
|-------------------------------------|-------------------------------------|
| 1. Right Apical Lobe of Lung | 16. Left Auricle |
| 2. Right Auricle | 17. Coronary (A & V'S) |
| 3. Cardiac Lobe of Lung | 18. Left Ventricle |
| 4. Right Ventricle | 19. Left Diaphragmatic Lobe of Lung |
| 5. Right Diaphragmatic Lobe of Lung | 20. Intermediate Lobe of Lung |
| 6. Diaphragm | 21. Diaphragm |
| 7. Left Central Lobe of Liver | 22. Left Lateral Lobe of Liver |
| 8. Gall Bladder | 23. Umbilical (V) |
| 9. Right Lateral Lobe of Liver | 24. Stomach |
| 10. Duodenum | 25. Epigastric (A) |
| 11. Spiral Colon (Reflected) | 26. Spleen |
| 12. Caecum (Reflected) | 27. Pancreas |
| 13. Mesentery | 28. Small Intestines |
| 14. Anterior Vena Cava | |
| 15. Pulmonary (A) | |

- | |
|--------------------------------------|
| 1. Hemiazygous (V) |
| 2. Left Diaphragmatic Lobe of Lung |
| 3. Stomach |
| 4. Small Intestine |
| 5. Anterior Vena Cava |
| 6. Right Apical Lobe of Lung |
| 7. Aorta |
| 8. Trachea |
| 9. Thoracic Aorta |
| 10. Esophagus |
| 11. Right Diaphragmatic Lobe of Lung |
| 12. Diaphragm |
| 13. Right Lateral Lobe of Liver |
| 14. Spiral Colon (Reflected) |
| 15. Abdominal Vena Cava |
| 16. Descending Part of Colon |

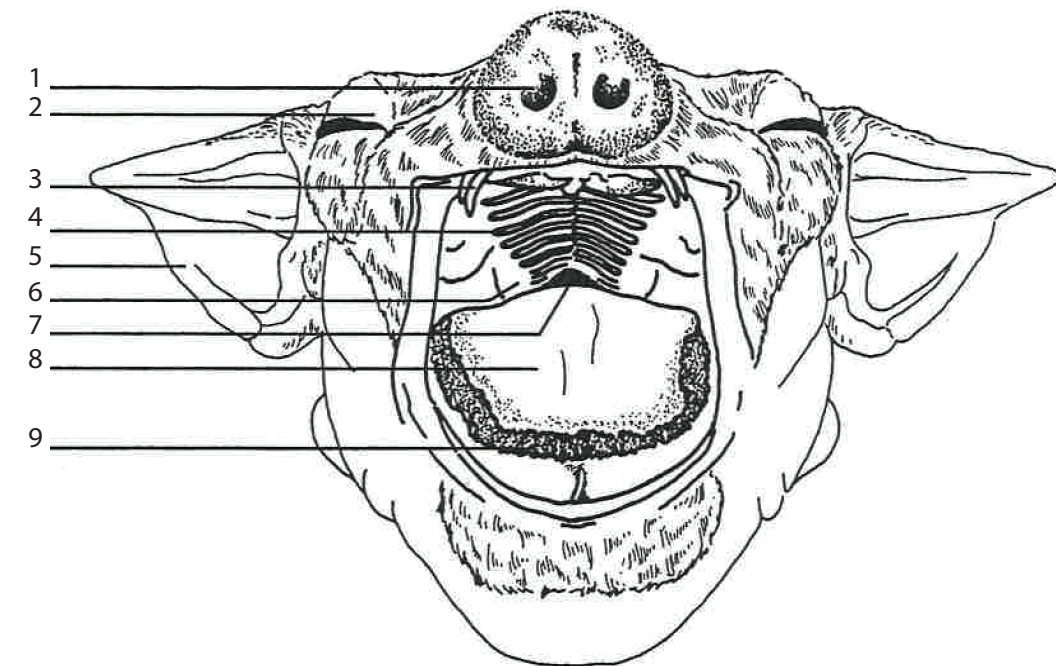
Ward's Fetal Pig Model

Sus scrofa

470004-386

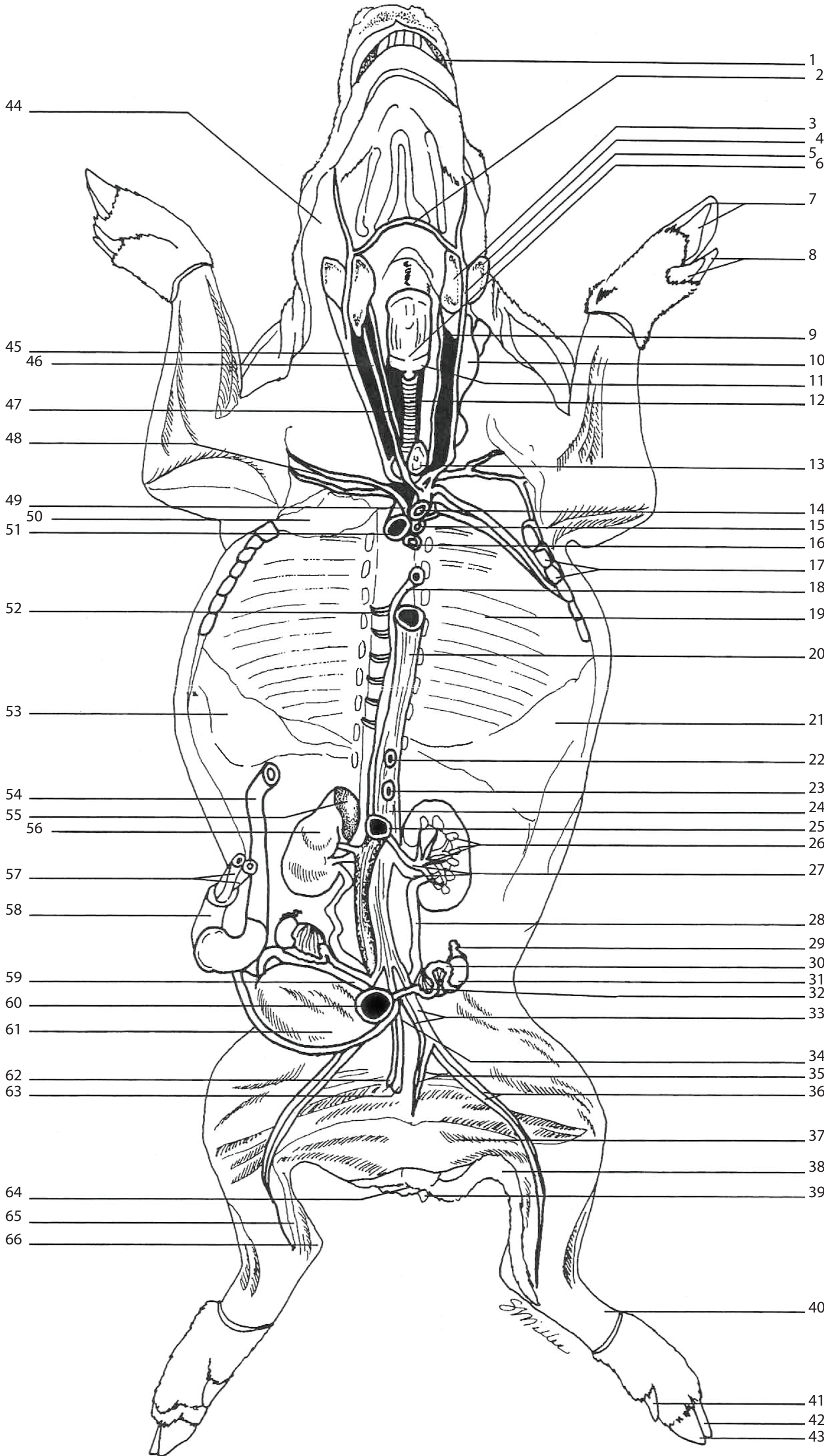
Key to Anatomical Features

Head



- | |
|------------------------------|
| 1. External Nares (Nostrils) |
| 2. Eyelid |
| 3. Teeth |
| 4. Hard Palate |
| 5. External Ear (Pinna) |
| 6. Soft Palate |
| 7. Region of Nasopharynx |
| 8. Tongue |
| 9. Tongue Papillae |

Ward's Fetal Pig Model (Ventral View)



1. Tongue
2. Transverse Jugular (V)
3. Sublingual Gland
4. Mandibular Gland
5. External Jugular (V)
6. Larynx
7. Phalange #4, & #5
8. Phalange #2, & #3
9. Common Carotid (A)
10. Parotid Gland (Reflected)
11. Thyroid Gland
12. Trachea
13. Portion of Thymus Gland
14. Superior Vena Cava
15. Brachiocephalic (A)
16. Esophagus
17. Ribs (cut)
18. Hemiazygous (V)
19. Rib
20. Thoracic Aorta
21. Diaphragm
22. Coeliac (A) - cut
23. Anterior Mesenteric (A) - cut
24. Abdominal Aorta
25. Inferior Vena Cava
26. Kidney: Pelvis (Inner)
Medulla (Middle)
Cortex (Outer)
27. Renal (A & V)
28. Ureter
29. Fallopian Tube (Oviduct)
30. Uterine Horn
31. Ovary
32. Broad Ligament
33. External Iliac (A & V)
34. Body of Uterus
35. Deep Femoral (A & V)
36. Femoral (A & V)
37. Gracilis Muscle
38. Tail
39. Genital Papilla
40. Extensor Tendons
41. Phalange #2
42. Phalange #4
43. Phalange #3
44. Masseter Muscle
45. External Jugular (V)
46. Internal Jugular (V)
47. Common Carotid (A)
48. Axillary (A)
49. Subclavian (A)
50. Thymus Gland (Reflected)
51. Trachea
52. Intercostal (A & V)
53. Diaphragm
54. Umbilical (V)
55. Right Adrenal Gland
56. Right Kidney
57. Umbilical (A's)
58. Umbilical Cord
59. Umbilical (A) - to Placenta
60. Rectum
61. Urinary Bladder
62. Urethra
63. Vagina
64. Anus
65. Achilles Tendon
66. Calcaneus